

## Initial Experience with the Benefits of Intraoperative Angiography in Surgery for Peripheral Arterial Occlusive Disease

Yao-Kuang Huang, MD; Po-Jen Ko, MD; Chi-Nan Tseng, MD; Hung-Chang Hsieh MD; Yun-Hun Liu, MD; Hui-Ping Liu, MD

**Background:** This preliminary investigation evaluated the procedures for intraoperative angiography-assisted peripheral vascular revascularization in a teaching hospital.

**Methods:** Between August 2000 and July 2001, intraoperative angiography with or without intervention was applied during surgery for peripheral arterial occlusive disease (PAOD) in 11 patients. Intraoperative angiography was employed to: (1) decide the best possible bypass graft outlet, (2) ensure the quality of the distal anastomosis of the bypass graft, (3) assist in the thrombectomy procedure, and (4) perform concomitant balloon angioplasty of vascular stenoses. Follow-up was conducted based on the clinical status, duplex scans, or angiographic surveillance.

**Results:** The 7 procedures for chronic PAOD included 4 adjuvant intraoperative angioplasties. Amputation was required in 1 patient because the intraoperative angiography confirmed that no suitable distal bypass could be performed. The 4 procedures performed on acute ischemic limbs included 1 adjuvant intraoperative angioplasty and 1 arterial graft bypass. The immediate limb salvage rate was 81.8% (9/11), and the perioperative mortality rate was 8.3% (1/11). Additionally, the overall 1-year primary patency of the vessel/graft was 78% (7/9), immediate limb salvage was 81.8% (9/11), and 2-year survival was 81.8% (9/11).

**Conclusions:** Preliminary results presented herein confirm the variable usefulness of intraoperative interventional angiography in cases of peripheral arterial occlusive disease. From our results, we concluded that vascular surgeons should apply these endovascular therapeutic skills in their daily practice.  
(*Chang Gung Med J* 2004;27:741-9)

**Key words:** intraoperative angiography, interventional angioplasty, peripheral arterial occlusive disease.

Vascular surgeons have, in practice, managed patients with a wide range of vascular diseases

using the conventionally adopted open surgical method. However, recently developed techniques for

---

From the Division of Thoracic and Cardiovascular Surgery, Chang Gung Memorial Hospital, Taipei and Chang Gung University, Taoyuan.

Received: May 26, 2004; Accept: Jul. 28, 2004

Address for reprints: Dr. Yun-Hen Liu, Division of Thoracic and Cardiovascular Surgery, Chang Gung Memorial Hospital, No. 5, Fushing St., Gueishan Shiang, Taoyuan, Taiwan 333, R.O.C. Tel.: 886-3-3281200; Fax: 886-3-3285818; E-mail: huang137@cgmh.org.tw

endovascular therapy have significantly changed the practice of vascular surgery. With improvements in diagnostic angiography and interventional radiology as well as refinements of new endovascular techniques, increasing numbers of vascular lesions can be managed less invasively. Since vascular surgeons are responsible for refining surgical procedures and reducing the invasiveness of vascular surgery, increasing numbers of surgeons are incorporating intraoperative angiography into the practice of vascular procedures.<sup>(1-6)</sup>

Surgery for peripheral arterial occlusive disease (PAOD) is traditionally performed in an open manner. Vascular surgeons frequently apply surgical techniques such as endarterectomy, thromboembolectomy, and bypass graft implantation during an open procedure to revascularize the arteries distal to the occlusive segments. Preoperative diagnostic angiography remains the gold standard for determining a suitable operative procedure. We hypothesized that using the technique of intraoperative angiography and endovascular intervention can improve judgments regarding surgery and ensure its effectiveness. This investigation presents our initial experience with the utility of using conventional portable angiography imaging and interventional techniques in a surgically based program to treat arterial occlusive disease.

## METHODS

This study retrospectively reviewed 11 consecutive patients with chronic or acute PAOD who had been surgically treated with intraoperative angiographic assistance between August 2000 and July 2001 by the same surgeon. Patients were considered candidates for surgery with vascular intervention if they reported lifestyle-limiting claudication refractory to standard exercise regimens and smoking cessation, or alternatively suffered from resting pain or ischemic tissue loss. Either angiography or duplex ultrasonography was conducted before surgery to identify lesions that were potentially amenable to treatment. We did not perform routine angiography before the operation in cases of acute PAOD, because this may have delayed definite revascularization beyond the time limit for limb salvage. The clinical manifestations, operative methods, and results were reviewed and are discussed.

Patients were classified based on their symptoms using recommendations outlined by the Ad Hoc Subcommittee on Reporting Standards for Endovascular Procedures. The clinical grades I (claudication), II (resting pain), and III (tissue loss) were determined for all patients. Additionally, Doppler-derived segmental pressure and computed ankle-brachial indices (ABIs), thigh-brachial indices (TBIs), Doppler scans, and preoperative angiography were obtained in all cases before surgery to facilitate preoperative planning.

Patients were operated on in the operative suite under regional anesthesia, with a vascular approach (usually the femoral arteries) being performed using a cut-down method. Intra-operative angiography imaging was performed with a portable C-arm digital substation arteriography system (OEC Medical System, Salt Lake City, UT, USA). Intraoperative angiography was performed by manual injection of contrast medium to confirm the preoperative diagnosis and to assist in determining a suitable outflow tract in cases requiring bypass after exploring the target vessels. The main procedures, including bypass surgery, a thromboembolectomy, or an endarterectomy, were performed in a standard fashion. After completing the main procedure, intraoperative angiography was repeated to confirm the thoroughness of the procedure. Standard anteroposterior views were routinely augmented with oblique views, and a small amount of contrast material was manually injected to confirm the location and severity of occlusive lesions. Based on the intraoperative angiography, a repeated thrombectomy, revision of the bypass anastomosis, or concomitant angioplastic procedures of the inlet or outlet vessels may have been performed to ensure the surgical results if necessary. That is, an attempt was made to fix every lesion found using intraoperative angiography, either endovascularly or surgically, to optimize the distal revascularization.

In summary, intraoperative angiography was applied during surgery in 11 patients with acutely or chronically ischemic legs. The male-to-female distribution in the sample was 8 to 3, and the mean age of the treated patients was 67.5 (range, 43 to 86) years. Table 1 lists the comorbid illnesses and selected risk factors of the patients, the role of intraoperative angiography, and the main traditional vascular arterial procedure.

**Table 1.** Clinical Characteristics and Interventional Procedures

Patient	Age (yr)/ Gender	Diagnosis and comorbidity	Pre-op clinical status	Intraoperative angiography and/or endovascular procedure	Main open procedure
1	58/M	Chronic PAOD, CVA	I	IBA for iliac arterial stenosis	Endarterectomy
2	76/M	Chronic PAOD, CVA, HTN, Af	II	Angiography for distal anastomosis site selection	Femoropopliteal bypass
3	61/F	Chronic PAOD, DM, HTN	III	IBA for SFA focal stenosis	Endarterectomy
4	71/M	Acute PAOD, CVA, HTN, DM, Af, ESRD	III	IBA for SFA focal stenosis; distal runoff check followed by a repeated embolectomy	Thromboembolectomy
5	69/M	Chronic PAOD, CVA, Af	III	IBA for left iliac artery stenosis; distal anastomosis site selection	Femoropopliteal bypass
6	86/F	Chronic PAOD of the popliteal a., DM, HTN	II	IBA for post-anastomotic stenosis	Left femoropopliteal bypass
7	77/M	Chronic PAOD, Burger's disease, HTN, DM, smoking	III	Angiography showed poor distal runoff	Vascular exploration, AK amputation
8	79/F	Chronic PAOD, DM, chronic renal insufficiency	II	Intraoperative angiography to select the crural receiving vessel	Femoral-crural bypass
9	43/M	Acute PAOD, upper extremity	II	Intraoperative angiography followed by a graft bypass	Subclavian artery bypass
10	77/M	Acute PAOD, smoking, ESRD, Af	III	Check of distal runoff followed by a repeated embolectomy	Thromboembolectomy
11	46/M	Acute PAOD, smoking, HTN, DM	II	Check of distal runoff followed by a repeated embolectomy	Thromboembolectomy

**Abbreviations:** M: male; F: female; PAOD: peripheral arterial occlusive disease; CVA: cerebral vascular accident; DM: diabetes mellitus; HTN: hypertension; Af: atrial fibrillation; ESRD: end-stage renal disease; IBA: intraluminal balloon angioplasty; SFA: superficial femoral artery.

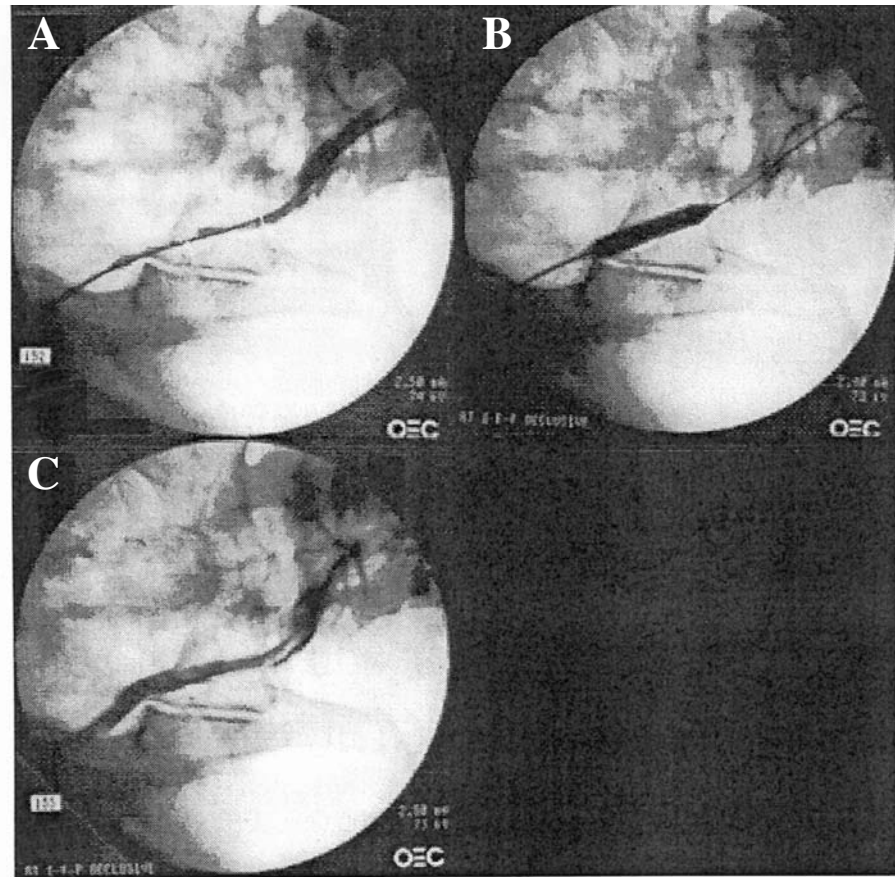
The study sample included 5 intraluminal balloon angioplastic (IBA) (Fig. 1) procedures and 5 arterial bypass grafts. Among the 5 angioplastic procedures (2 of the iliac artery, 2 of the superficial femoral artery and 1 postanastomotic crural artery balloon angioplasty), 3 were performed together with a conventional femoropopliteal arterial bypass. Moreover, 2 of the procedures were adjunct to traditional endarterectomy or thromboembolectomy procedures.

## RESULTS

Four patients presented with acutely ischemic legs, and 7 presented with chronically ischemic legs in this investigation. Among the 7 procedures in cases of chronic PAOD, 4 adjuvant intraoperative

angioplasties were performed to improve the inflow or outflow tracts. Amputation above the knee was performed in 1 patient because the intraoperative angiography confirmed that there was no other option for performing a suitable distal bypass (patient 7, with Burger's disease). Additionally, distal runoff of all 5 bypass grafts was confirmed by intraoperative angiography to be patent immediately after the anastomosis.

Among the 4 procedures performed for acute ischemic limbs, 1 adjuvant intraoperative angioplasty was performed to address the residual superficial femoral arterial stenosis. A repeated thrombectomy using the thrombectomy catheter was performed in 2 patients because of residual thrombosis which was found during intraoperative angiography. Furthermore, 1 arterial graft bypass was performed in



**Figs. 1** (A) Critical stenosis identified in the left external iliac artery. (B) Intraoperative intraluminal balloon angioplasty; balloon size: 9 mm × 4 cm. (C) Neither residual stenosis nor extravasation found after the procedure.

**Table 2.** Surgical Results and Follow-Up Data

Patient	Limb salvage	Primary/secondary patency/total follow-up (month)	Mortality	Medication	Outcome
1	Yes	20/20/20	No	Warfarin, cilostazol	No claudication
2	Yes	12/12/12	No	Aspirin, cilostazol	No claudication
3	Yes	20/20/20	No		No claudication
4	Yes	5/5/18	No		Amputation due to recurrent embolization of leg vessels 5 months later
5	Yes		Yes	Warfarin, cilostazol	Postoperative acute myocardial infarction
6	Yes	8/8/16	No	Warfarin	Amputation due to progression of disease 8 months later
7	No	0/0/40	No	Cilostazol	Amputation due to poor distal runoff
8	Yes	12/12/12	No	Warfarin, analgesia	Symptom free
9	Yes	31/43/43	No	Warfarin	Recurrent thrombosis 2 years later; reoperation
10	Yes		Yes	Nil	Limb improved following bypass, expired due to pneumonia
11	Yes	15/15/15	No	Cilostazol	Symptom free

response to the refractory lesions identified on intraoperative angiography.

Follow-up was performed based on the clinical status, duplex scans, or angiographic surveillance. Table 2 summarizes the follow-up results in these patients. Two mortalities occurred. One death resulted from postoperative pneumonia. The other patient suffered complications of a postoperative myocardial infarction for wound debridement and died 4 months after the surgery. The overall 1-year primary patency of the vessel/graft was 78% (7/9), immediate limb salvage was 81.8% (9/11), and 2-year survival was 81.8 % (9/11).

## DISCUSSION

The therapeutic endovascular procedure was first reported by Forgarty et al. in 1963.<sup>(7)</sup> They performed a thromboembolectomy using a balloon catheter. Dotter and Judkins subsequently introduced the concepts of balloon angioplasty, and recommended the transluminal dilatation of occlusive vascular lesions with a coaxial dilating catheter.<sup>(8)</sup> This approach achieved significant improvements in the techniques of vascular surgery.

Initially, evaluations using the angiographic procedure were performed for diagnostic purposes before surgical reconstruction. Most surgeons released these diagnostic responsibilities to their colleagues in radiology. The subspecialty of interventional radiology later developed with progress in endovascular techniques and devices.

With the expansion of interventional radiological and angioplastic techniques, indications for endovascular treatment have broadened, and have even replaced some forms of vascular surgery. Although these nonsurgical methods were initially criticized for some of their deficiencies, those criticisms gradually dissipated as successful reports accumulated indicating that balloon angioplasty could be as effective and safe as conventional vascular surgery.

Surgeons then cautiously began to consider their role in treating patients who are candidates for endovascular intervention.<sup>(9)</sup> Limitations of this role have become evident in the face of the increasing complexity of vascular surgery. Realizing that evolving endovascular technology may replace standard surgical alternatives, and unsatisfied with their limit-

ed role in the management of patients, numerous surgeons have advocated an expanded role in performing endovascular procedures. More surgeons have incorporated the concepts of intraoperative angiography and endovascular treatment into their open vascular surgery to enhance the surgical results and minimize the surgical invasiveness.<sup>(10-18)</sup>

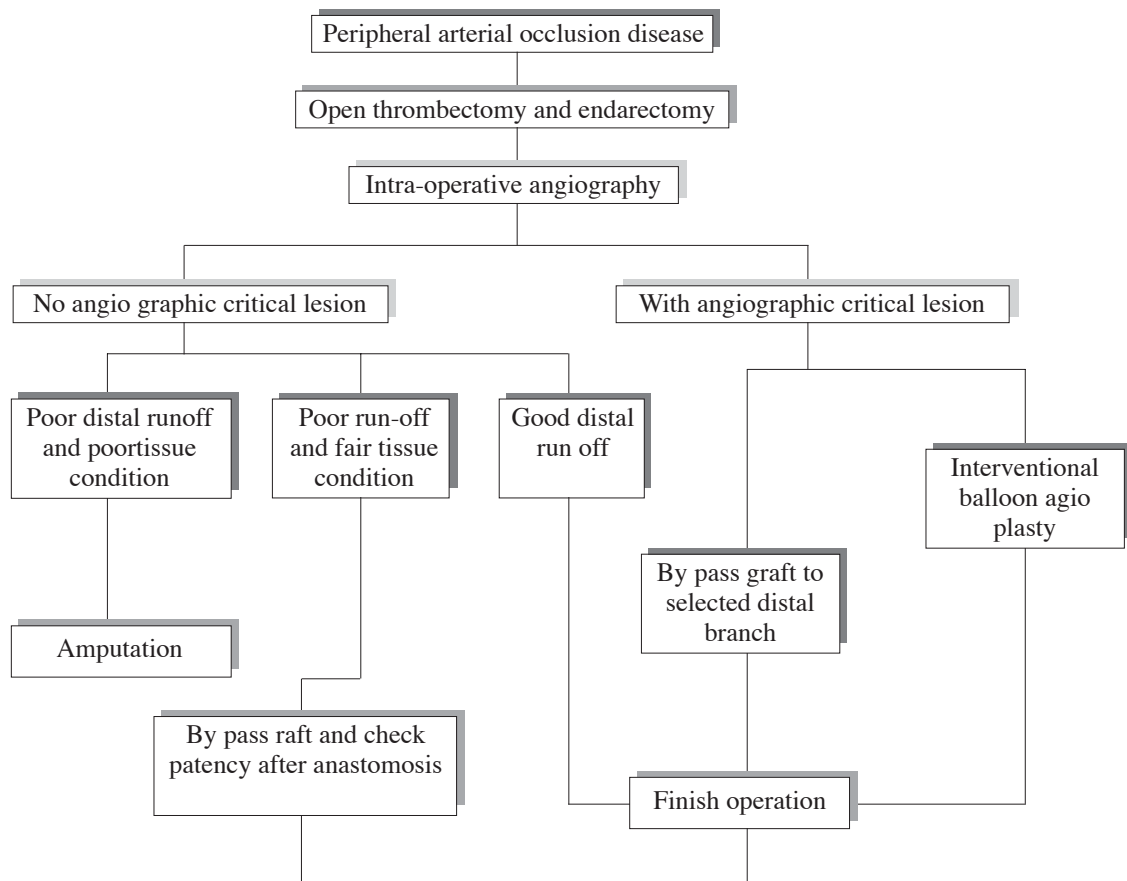
The operating room was used as the site for applying the protocol of intraoperative angiography and endovascular intervention during the open surgery in this study. The C-arm imaging available in the operating suite was found to be adequate for performing peripheral arterial angioplasty. Aortoiliac angioplasty is sometimes restricted by the foundation of the surgical table. This problem was resolved after introducing an elongated angiographic table.

Indications for surgical intervention included disabling claudication in 1 patient, resting pain in 4 patients, and tissue loss in 5 patients. The flow chart shown in Figure 2 was begun once the patients were enrolled in the angiographically assisted vascular surgery.

All patients were checked using intraoperative angiography, which can assist in pre-anastomosis management (identifying critical stenoses or selecting the site of the distal anastomosis), or post-anastomosis management (checking the anastomotic patency and distal runoff).

A combined approach using both surgical revascularization and angioplasty to deal with chronic PAOD has been proposed by some surgeons for multi-segmental arterial disease.<sup>(15,19-21)</sup> In our experience, intraoperative angiography and angioplasty may provide versatile benefits in managing peripheral arterial occlusive disease, particularly in the lower extremities. First, this investigation identified anatomically significant stenoses and conducted intraluminal balloon angioplasty (IBA) in selected patients. IBA may increase arterial inflow or outflow, providing alternatives for further vascular reconstruction (e.g., changing from an axillofemoropopliteal bypass to a femoropopliteal bypass after successful IBA for iliac arterial stenosis). Second, the angio-assisted vascular bypass provided real-time crural vessel mapping, which helped select the best site for distal anastomosis in the case of long segmental thigh arterial stenosis. Finally, the crural distal runoff should be checked after the completion of all bypass graft anastomoses. If the crural tissue





**Fig. 2** Decision making in peripheral arterial occlusive disease with intraoperative angiography-assisted vascular surgery.

condition fails to improve despite good anastomosis and patent distal runoff, primary amputation may be performed as a part of the same operation.

For procedures dealing with thromboembolic disease, intraoperative angiography also offers certain benefits.<sup>(22,23)</sup> First, intraoperative angiography can benefit the thromboembolectomy procedures by incorporating guidewire and catheter techniques into the procedure rather than performing a blind thrombectomy. With real-time guidance by angiography, the thrombectomy catheter can be introduced into selected vessels such as the crural vessels to enhance the effectiveness and selectivity of the embolectomy. Second, it helps to confirm the effectiveness of the procedure by checking the distal runoff and residual thrombus following the initial thrombectomy. In cases involving a residual throm-

bus, the catheter thrombectomy can be repeated until the thrombus is completely removed. Third, intraoperative angiography can be used to suggest some adjuvant procedures, for example balloon angioplasty or a graft bypass for a residual stenosis or occlusion, to improve the outcome as necessary. Thus the effectiveness of the thromboembolectomy procedure is improved.

The short- and long-term results of vascular surgery are known to be markedly influenced by lesion characteristics. Silva et al. considered a stenotic lesion length of less than 5 cm to be a positive predictor of clinical success. Factors such as lesion location, runoff status, and the distal tissue condition also may significantly influence the initial results.<sup>(24)</sup> Surgeons who perform the intraoperative endovascular procedure should be familiar with the principles

of transluminal angioplasty. Thus, surgical bypass should promptly be performed in lesions that cannot be dealt with intraoperatively via an endovascular procedure. That is to say, with the ability to perform intraoperative angiography and endovascular therapies, surgeons have more treatment modalities from which to choose when facing peripheral vascular disease. Thus they can smartly use hybrid procedures to improve the quality of the open surgery.

In conclusion, this study recommends that vascular surgeons become involved in performing and refining endovascular procedures in the operating room. The preliminary results presented herein demonstrate the possibilities and value of simultaneously performing an angiographic intervention and therapeutic vascular surgery in the operating room. Further study is necessary to clarify the long-term results of angio-assisted vascular surgery for PAOD. The experience presented herein confirms that therapeutic endovascular intervention facilitates the refinement of future open vascular surgeries by incorporating angioplasty and stenting procedures into the traditional open vascular revascularization, and assures hemodynamic results following an open procedure. This study proposes that vascular surgeons take advantage of these endovascular therapeutic skills in their daily practice.

## REFERENCES

1. Ko PJ, Liu YH, Hsieh HC, Chu JJ, Lin PJ. Initial experience during balloon angioplasty assisted surgical thrombectomy for thrombosed hemodialysis grafts. *Chang Gung Med J* 2003;26:178-83.
2. al-Salman MM. Intraoperative balloon angioplasty: a useful adjunct. *Int Surg* 1998;83:79-83.
3. al-Salman M, Doyle DL, Hsiang YN, Fry PD, Fragoso M. Intraoperative balloon angioplasty: a surgical approach. *Can J Surg* 1992;35:265-8.
4. Dardik II, Ibrahim IB, Sprayregen S, Veith F, Dardik H. Routine intraoperative angiography. An essential adjunct in vascular surgery. *Arch Surg* 1975;110:184-90.
5. Zuhlke HV, Sorensen R, Haring R, Konradt J. Intraoperative open transluminal angioplasty (IOTA). *Chirurg* 1981;52:265-70.
6. Donaldson MC, Rosenberg JM. Intraoperative arterial balloon angioplasty. *Conn Med* 1986;50:713-5.
7. Fogarty TJ, Cranley JJ, Krause RJ, Strasser ES, Hafner CD. A method for extraction of arterial emboli and thrombi. *Surg Gynecol Obstet* 1963;116:241-4.
8. Dotter CT, Judkins MP. Transluminal recanalization in occlusive disease of the leg arteries. *Gp* 1968;37:98-106.
9. McCleary AJ, Gough MJ. Vascular surgeon's experience with intraoperative angioplasty. *ANZ J Surg* 2001;71:565-9.
10. Cheng SW, Ting AC, Lau H. Combined long-segment angioplasty and stenting of the superficial femoral artery and popliteal-distal bypass for limb salvage. *J Cardiovasc Surg (Torino)* 2000;41:109-12.
11. Lau H, Cheng SW. Intraoperative endovascular angioplasty and stenting of iliac artery: an adjunct to femoropopliteal bypass. *J Am Coll Surg* 1998;186:408-15.
12. Lopez-Galarza LA, Ray LI, Rodriguez-Lopez J, Diethrich EB. Combined percutaneous transluminal angioplasty, iliac stent deployment, and femorofemoral bypass for bilateral aortoiliac occlusive disease. *J Am Coll Surg* 1997;184:249-58.
13. Katz SG, Kohl RD, Yellin A. Iliac angioplasty as a prelude to distal arterial bypass. *J Am Coll Surg* 1994;179:577-82.
14. van der Vliet JA, Mulling FJ, Heijstraten FM, Reinaerts HH, Buskens FG. Femoropopliteal arterial reconstruction with intraoperative iliac transluminal angioplasty for disabling claudication: results of a combined approach. *Eur J Vasc Surg* 1992;6:607-9.
15. Wilson SE, White GH, Wolf G, Cross AP. Proximal percutaneous balloon angioplasty and distal bypass for multi-level arterial occlusion. Veterans Administration Cooperative Study No. 199. *Ann Vasc Surg* 1990;4:351-5.
16. Griffith CD, Harrison JD, Gregson RH, Makin GS, Hopkinson BR. Transluminal iliac angioplasty with distal bypass surgery in patients with critical limb ischaemia. *J R Coll Surg Edinb* 1989;34:253-5.
17. Kugel RD, Pereyra R. Combined femorotibial bypass and distal intraoperative transluminal angioplasty. *J Vasc Surg* 1986;4:533-5.
18. Queral LA, Criado FJ, Patten P. Retrograde iliofemoral endarterectomy facilitated by balloon angioplasty. *J Vasc Surg* 1995;22:742-50.
19. Adovasio R, Chiarandini S, Ziani B, Pozzi Mucelli R. Intraoperative iliac angioplasty and distal revascularization: is it an efficacious method in the high-risk patient? *Angiologia* 1992;44:217-20.
20. Aburahma AF, Robinson PA, Cook CC, Hopkins ES. Selecting patients for combined femorofemoral bypass grafting and iliac balloon angioplasty and stenting for bilateral iliac disease. *J Vasc Surg* 2001;33:S93-9.
21. Schneider PA, Caps MT, Ogawa DY, Hayman ES. Intraoperative superficial femoral artery balloon angioplasty and popliteal to distal bypass graft: an option for combined open and endovascular treatment of diabetic gangrene. *J Vasc Surg* 2001;33:955-62.
22. Crolla RM, van de Pavoordt ED, Moll FL. Intraoperative digital subtraction angiography after thromboembolism: preliminary experience. *J Endovasc Surg* 1995;2:168-71.
23. Ammar AD, Hutchinson SA. Management of acute

- infrainguinal arterial thrombosis: combined intraoperative balloon thrombectomy with balloon angioplasty: a preliminary report. *Surgery* 1987;101:176-80.
24. Silva MB, Jr., Hobson RW 2nd, Jamil Z, Araki CT, Goldberg MC, Haser PB, Lee BC, Padberg FT, Jr., Pappas PJ, Teehan EP. A program of operative angioplasty: endovascular intervention and the vascular surgeon. *J Vasc Surg* 1996;24:963-73.



## 阻塞性週邊血管疾病之血管外科手術合併術中血管攝影 輔助技術之初期經驗

黃耀廣 柯博仁 曾棋南 謝宏昌 劉永恆 劉會平

**背景：**以術中血管攝影輔助血管手術為近年之趨勢。

**方法：**自2000年8月至2001年7月，我們應用血管攝影或是侵入性血管治療於11個阻塞性週邊血管疾病之病人。

**結果：**有7項手術，包括4項侵入性血管整形術應用於慢性阻塞性週邊血管疾病人；另外有4項手術，包括1項侵入性血管整形術和1項繞道手術應用於急性阻塞性週邊血管疾病人。立即肢體保存為9/11，手術相關死亡為1/11，一年之血管暢通為7/9。

**結論：**此一初期的結果顯示血管攝影和侵入性血管整形術提供傳統血管手術之多樣輔助和價值，包含下刀前(選擇和確定目標血管)、術中(氣球血管整形及輔助血塊清除)和術後(確定吻合暢通)。血管攝影和侵入性血管攝影已成為現代血管外科醫師面對更複雜疾病時應具備的工具之一。

(長庚醫誌2004;27:741-9)

**關鍵字：**術中血管攝影，侵入性血管整形術，阻塞性週邊血管疾病。

---

長庚紀念醫院 台北院區 胸腔及心臟血管外科系，長庚大學

受文日期：民國93年5月26日；接受刊載：民國93年7月28日。

索取抽印本處：劉永恆醫師，長庚紀念醫院 胸腔及心臟血管外科系。桃園縣333龜山鄉復興街5號。Tel.: (03)3281200;

Fax: (03)3285818; E-mail: huang137@cgmh.org.tw